

# Online Guidance of Tumor Targeted Prostate Brachytherapy using Histologically Referenced MRI

<sup>1</sup>Princess Margaret Hospital, University of Toronto, Toronto, Ontario, Canada, <sup>2</sup>Sentinelle Medical Inc, <sup>3</sup>Odette Cancer Center, University of Toronto

## Abstract

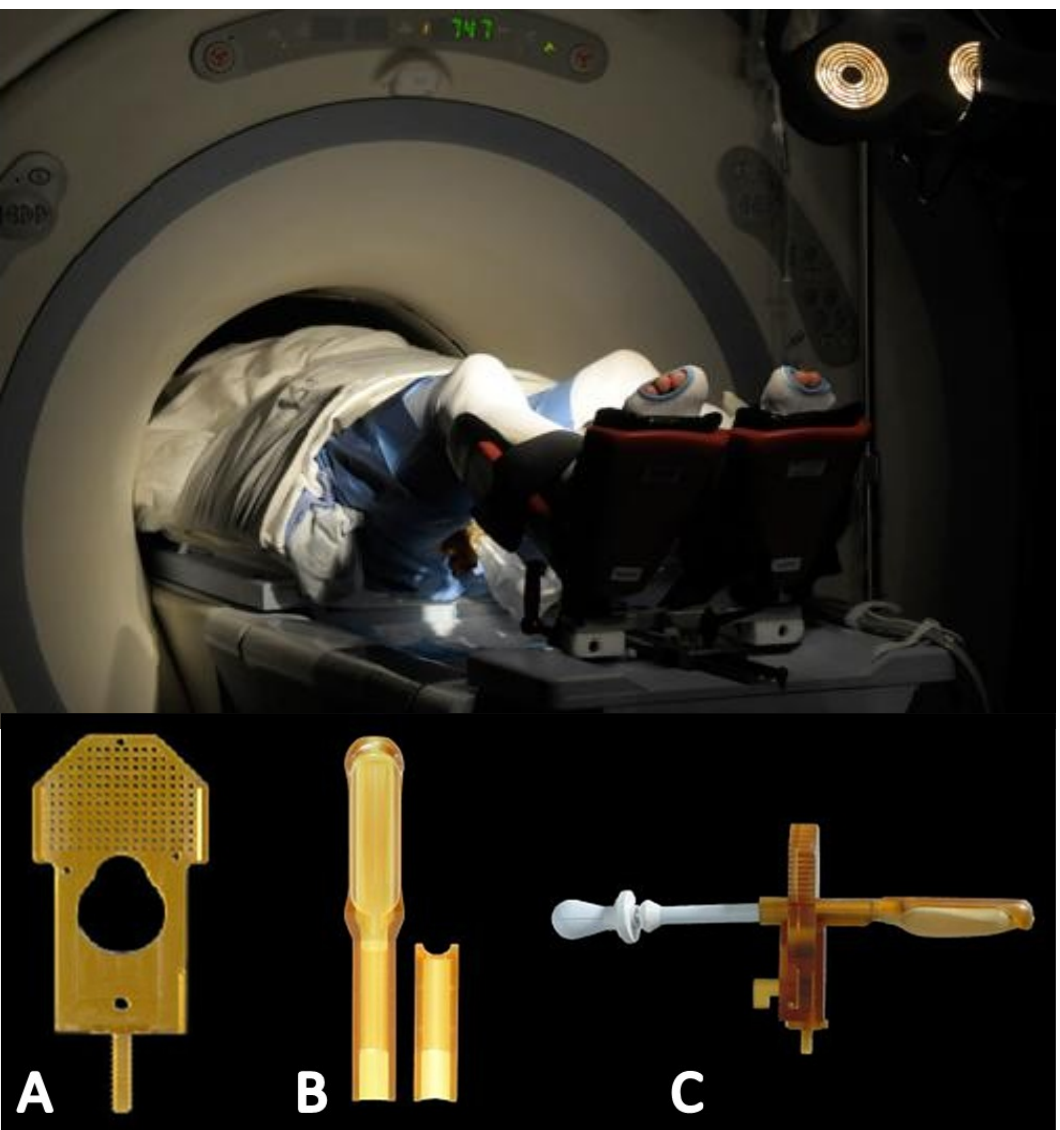**Purpose:** While multi-parametric MRI can accurately identify regions of tumor burden within the prostate, its performance in delineating the boundaries of tumor targets for focal therapeutic intervention has not been determined. Here we report technical and clinical performance of a needle navigation system where pathologically referenced multi-parametric MRI guidance improved the determination of tumor boundaries, and enabled tumor-targeted HDR brachytherapy.

**Methods:** The navigation system utilizes a dedicated interventional MRI table (Sentinelle Medical Inc), which provides access to the perineum in a stable supine patient position within a 1.5T GE Signa scanner, and a stereotactic transperineal template assembly. The procedure involves multiparametric diagnostic imaging of the prostate gland, registration of the stereotactic system, navigation tools for needle guidance, and 3D needle verification imaging. Patients with suspicion of local recurrence after radiotherapy were enrolled on a prospective clinical trial of MRI-guided biopsy, where a single integrated diagnostic imaging and biopsy procedure was performed under propofol sedation. Core samples were obtained at the boundary of tumors identified on MRI, and from all non-suspicious sextants. Those patients with visible and histologically referenced focal recurrences were eligible for tumor-targeted salvage HDR brachytherapy, each receiving two fractions (11Gy) over 14 days. The tumor target was defined as the shared boundary of suspicious MRI features and malignant biopsy cores mapped onto T2-weighted images.

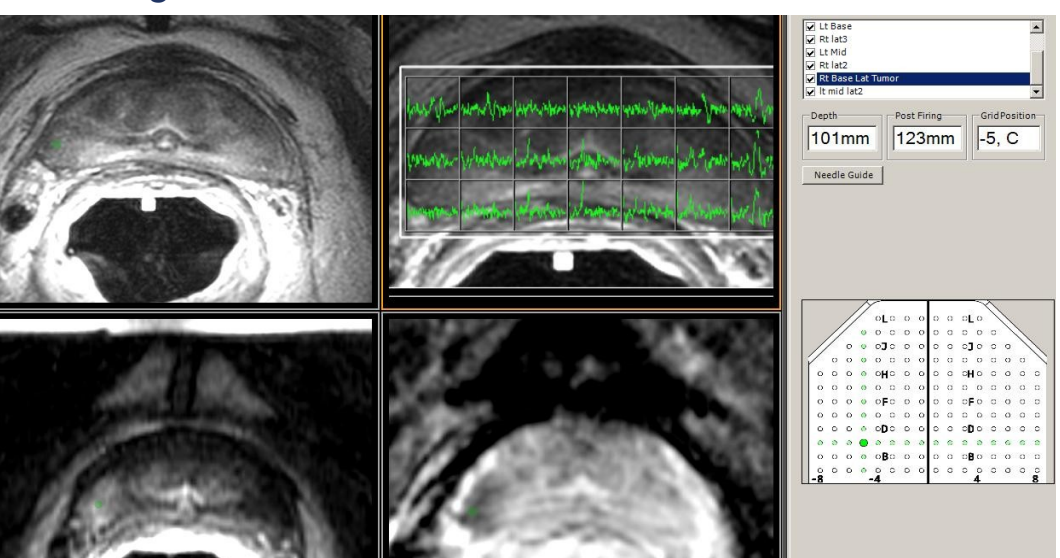
**Results:** Eighteen patients (age 63-83, mean 72) received MRI-guided prostate biopsy at biochemical failure 2-11 years after radiotherapy (mean 6.3 yrs), and 4 patients have proceeded to salvage HDR brachytherapy to date. Most (15/18) were found to have local recurrence, including 11 patients with confirmed focal tumor visible on MRI and amenable to local salvage. Mean absolute in-plane stereotactic needle targeting accuracy was 2.2mm (SD 0.7mm), and biopsy core co-registration accuracy was sub-voxel. Excluding the first two patients, mean diagnostic MRI + biopsy procedure time was 80 min (55-142 min), while the mean imaging time for brachytherapy catheter insertion was 87.5min (69-100min). Tumor targets for HDR brachytherapy ranged from 1.8-4.3cc, representing 6-18% of the prostate volume. Needle core histological maps led to a change in tumor target boundary in all 4 patients, where the tumor target was enlarged in 3/4 patients.

**Conclusion:** Feasibility of integrating pathologically referenced multi-parametric MRI for online guidance of HDR prostate brachytherapy is demonstrated. The value of 3D imaging to document actual location of biopsy cores in reference to anatomic boundaries cannot be overstated. Online MRI needle guidance systems with accurate and responsive navigation help better define cancer features on MRI and enable tumor-targeted diagnostics and therapeutics.

## Methods



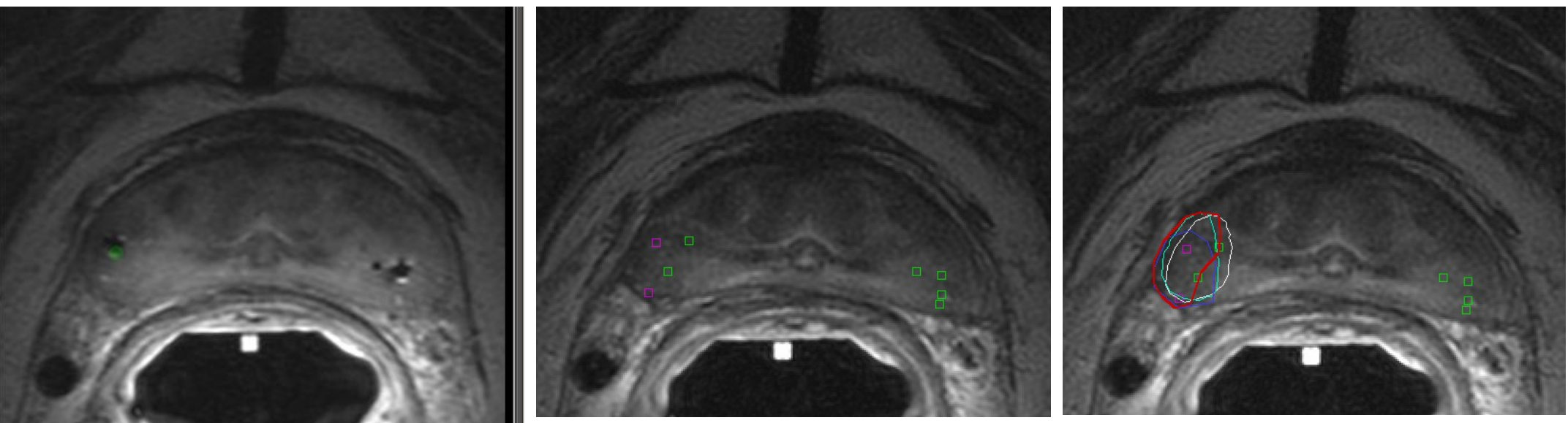
**Figure 1.** Dedicated interventional MRI table assembly providing pelvic access for transperineal stereotactic needle guidance.



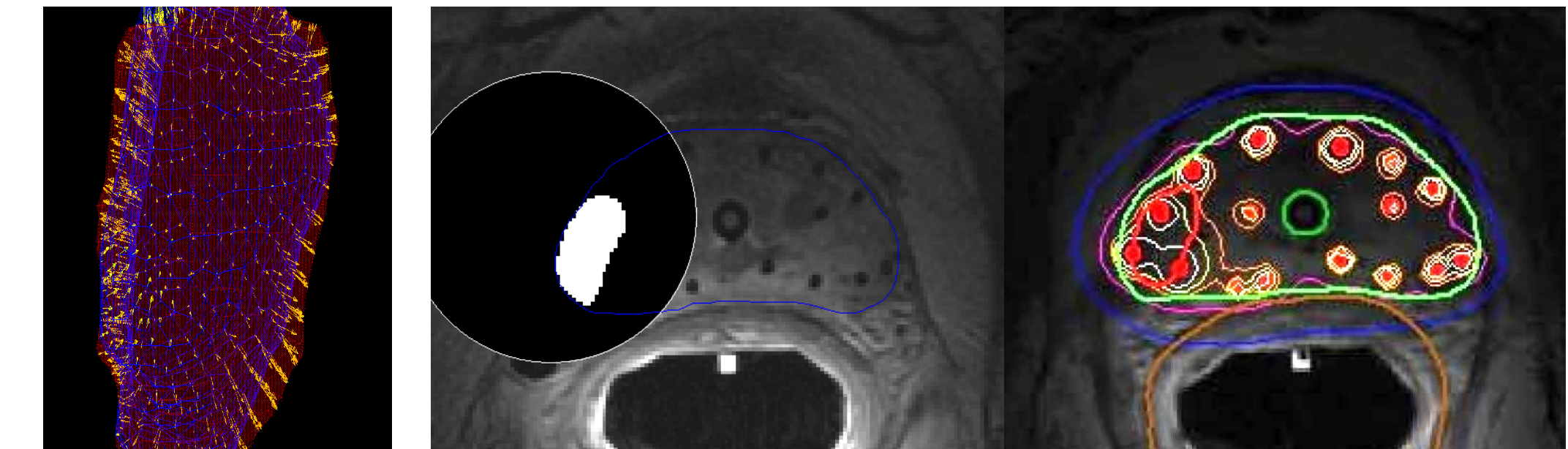
**Figure 2.** Navigation software (Aegis, Sentinelle Medical Inc.) displaying needle target (green) onto T2w images, MRSI, DCE, and ADC map depicting a suspicious tumor region.

- Patients with suspicion of local recurrence after RT were enrolled on a prospective clinical trial
- Integrated diagnostic imaging and biopsy procedure performed under propofol sedation.
- Core samples obtained at the boundary of tumors identified on MRI, and from non-suspicious sextants
- Patients with visible and histologically confirmed focal recurrences were eligible for tumor-targeted salvage HDR brachytherapy
- Tumor target defined as shared boundary of suspicious MRI features and malignant biopsy cores mapped onto T2-weighted images.

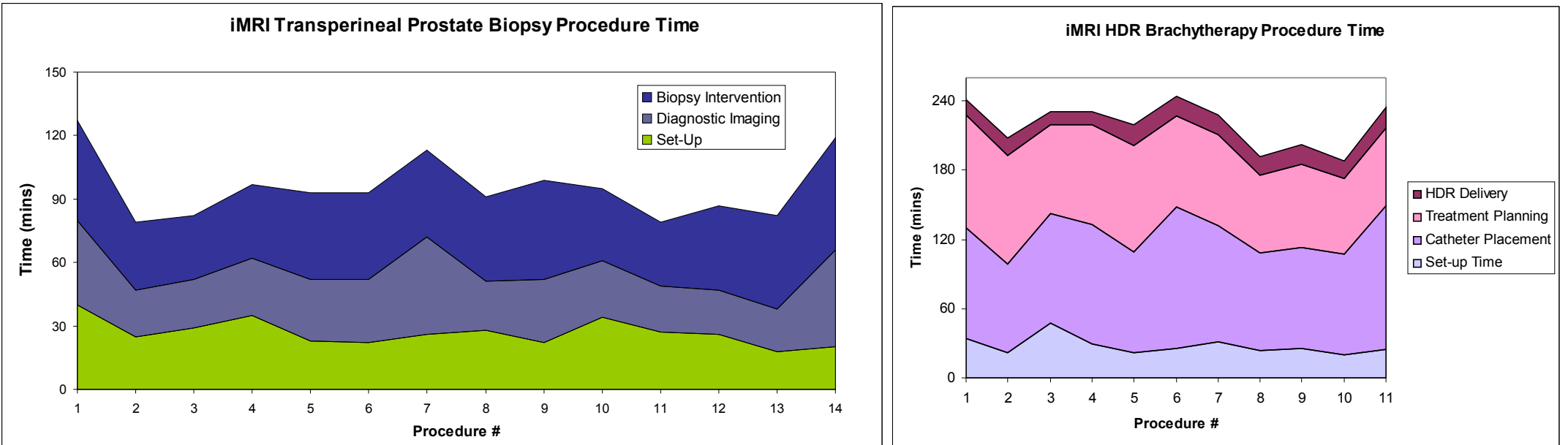
## Results



**Figure 3.** Needle verification images documenting actual location of 3 biopsy needles (signal voids R and L) in reference to intended target (green), and map of benign (green), malignant (pink) biopsy cores in reference to tumor boundaries delineated on DCE (light blue), ADC (white), and T2 (royal blue). The final tumor boundary (red) was revised laterally based on histological reference, thereby reducing the target volume for salvage HDR brachytherapy.



**Figure 4.** Deformable registration of prostate boundaries using FEM methods (Morpheus) maps the histologically referenced tumor boundaries onto HDR brachytherapy images for escalated dose prescription depicted on isodose maps (orange, 11Gy, pink 8Gy)



**Figure 5.** Time trends in feasibility. Mean MRI-Guided biopsy time was 80 min (55-128 min), while mean imaging time for brachytherapy catheter insertion was 87.5min (69-100min).

- Eighteen patients (age 63-83, mean 72) received MRI-guided prostate biopsy at biochemical failure 2-11 years after radiotherapy (mean 6.3 yrs)
- Most (15/18) were found to have local recurrence, including 11 patients with confirmed focal tumor visible on MRI and amenable to local salvage
- 5 patients have proceeded to salvage HDR brachytherapy to date

- Mean absolute in-plane stereotactic needle targeting accuracy was 2.2mm (SD 0.7mm)
- Small prostate displacements (mean 0.3mm) were observed during needle insertion, but
- Large variability in displacements (SD>1mm) mandates image registration for accurate biopsy core mapping
- Biopsy core co-registration accuracy is sub-voxel given minimal gland deformation during the integrated procedure and 3D documentation of needle core locations.
- Tumor targets for HDR brachytherapy ranged from 1.8-4.3cc, representing 6-18% of the prostate volume.
- Needle core histological maps led to a change in tumor target boundary in all 5 patients, where the tumor target was enlarged in 4/5 patients.
- Deformable registration using FEM methods is required due to variable deformation by the ERC between procedure.

## Conclusion

- Feasibility of integrating pathologically referenced multi-parametric MRI for online guidance of HDR prostate brachytherapy is demonstrated, but improvements in efficiency and workflow are required prior to wider adoption of the technique.
- The importance of 3D imaging to document actual location of biopsy cores in reference to anatomic boundaries cannot be overstated in the context of image-guided therapies.

- Online MRI needle guidance systems with accurate and responsive navigation help better define cancer features on MRI and enable tumor-targeted diagnostics and therapeutics.

## Objectives

- Multiparametric MRI can localize regions of disease burden within the prostate gland, but
- Accuracy in delineating tumor boundaries for focal therapy is less well understood. We sought to:
  1. Develop an online stereotactic and MRI-guided needle navigation system,
  2. Report technical performance in needle targeting accuracy,
  3. Determine clinical feasibility of MRI-guided tumor-targeted biopsy and brachytherapy,
  4. Present the concept of histologically referenced MRI to guide tumor-targeted therapy.